Management of Acute Coronary Syndrome

Dr. Oriba Dan Langoya

Physician & Head of Department Internal Medicine

St. Mary's Hospital Lacor

Honorary Lecturer, Faculty of Medicine

Gulu University

Defining Chest Pain



"Chest pain" suggestive of ischemia is not just discomfort in the chest; it can be discomfort in the shoulder, jaw, epigastric area, neck or back.



An initial assessment of chest pain is recommended to triage patients effectively on the basis of the likelihood that symptoms may be attributable to myocardial ischemia.



Chest pain should not be described as atypical, because it is not helpful in determining the cause and can be misinterpreted as benign in nature.



Chest pain should be described as cardiac, possibly cardiac, or noncardiac because these terms are more specific to the potential underlying diagnosis.

Pathophysiology of OMI

Thygesen K, Alpert JS, Jaffe AS, et al. Third universal definition of myocardial infarction. J Am Coll Cardiol 2012;60:1581.

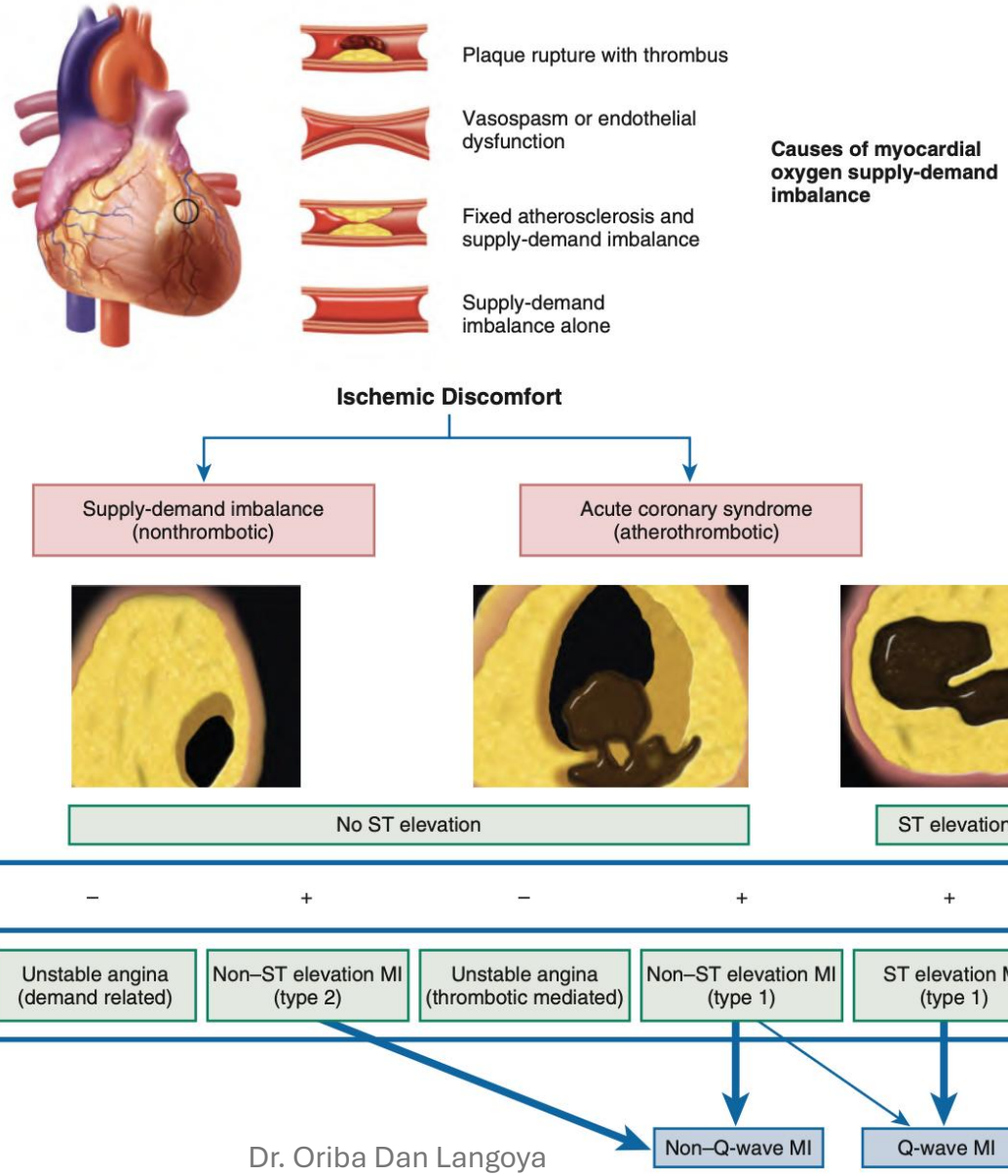

Early Care for Acute Symptoms

Patients presenting to the ED with nontraumatic chest pain

PRIORITIES

Evaluation of all patients to focus on early identification or exclusion of life-threatening causes such as:

- ACS
- Aortic Dissection
- Pulmonary Embolism
- Nonvascular Syndromes *(e.g., esophageal rupture, tension pneumothorax)*

FOCUSED HISTORY OF CHEST PAIN

Characteristics of chest pain:

- Nature
- Onset/Duration
- Location/Radiation
- Precipitating factors
- Relieving factors
- Associated symptoms

Cardiac Chest Pain Characteristics

Characteristics of chest pain:

- Retrosternal chest discomfort
- Gradual in intensity
- Precipitated by stress
- Radiation down arm or jaw
- Associated with dyspnea, nausea, lightheadedness

Physical Exam in Patients with Chest Pain

In patients presenting with chest pain, a focused cardiovascular examination should be performed initially to aid in the diagnosis of ACS or other potentially serious causes of chest pain (e.g., aortic dissection, PE, or esophageal rupture) and to identify complications (Class 1).

Emergent Clinical Syndromes and Assessment Findings

Acute Coronary Syndrome	Pulmonary Embolism	Aortic Dissection	Esophageal Rupture
• Diaphoresis • Tachypnea • Tachycardia • Hypotension • Crackles • S3 • MR murmur • Exam can be normal	• Tachycardia • Dyspnea • Pain with inspiration	• Extremity pulse differential • Abrupt onset of pain • Severe pain • Syncope	• Emesis • Subcutaneous emphysema • Pneumothorax • Unilateral decreased or absent breath sounds

Abbreviations: ACS indicates acute coronary syndrome; MR, mitral regurgitation; PE, pulmonary embolism; and S3, third heart sound.

Other causes of chest pain

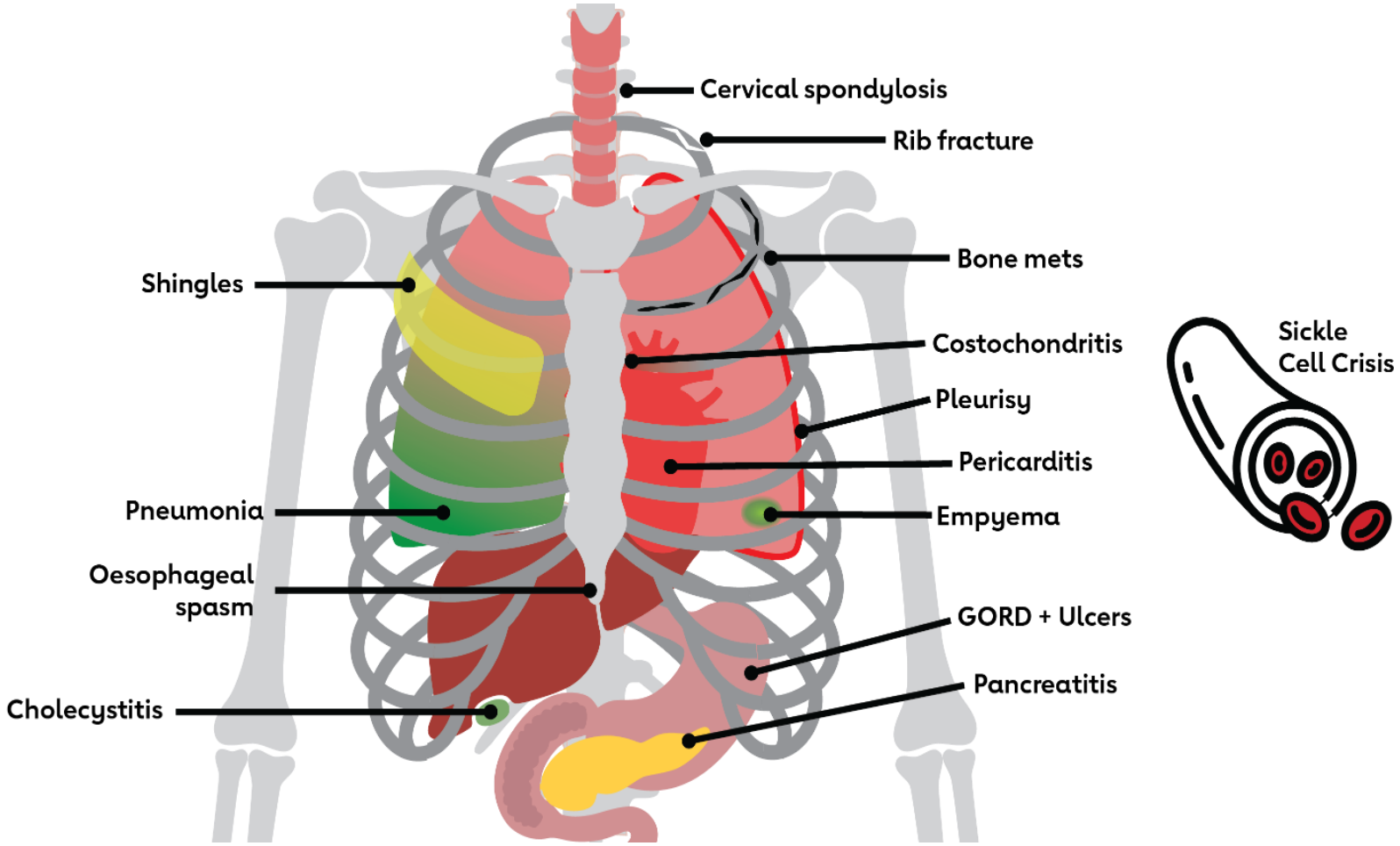

•**Abbreviations:** GORD indicates gastro-oesophageal reflux disease; and mets, metastasis.

Noncardiac Chest Pain: Differential Diagnoses

Respiratory

- PE
- Pneumothorax/ hemothorax
- Pneumomediastinum
- Pneumonia
- Bronchitis
- Pleural irritation
- Malignancy

Gastrointestinal

- Cholecystitis
- Pancreatitis
- Hiatal hernia
- GI reflux disease
- Gastritis/
- Esophagitis
- Peptic ulcer disease
- Esophageal spasm
- Dyspepsia

Chest Wall

- Costochondritis
- Chest wall trauma
- Herpes Zoster
- Cervical radiculopathy
- Breast disease
- Rib fracture
- Musculoskeletal injury

Psychological

- Panic disorder
- Anxiety
- Clinical Depression
- Somatization disorder
- Hypochondria

Other

- Hyperventilation syndrome
- Carbon monoxide poisoning
- Sarcoidosis
- Lead poisoning
- Prolapsed interverbal disc
- Thoracic outlet syndrome
- Sickle cell crisis
- Adverse medication effects

•**Abbreviations:** Gi indicates gastrointestinal; and PE, pulmonary embolus.

Physical Exam in Patients with Chest Pain; Other

Other Clinical Syndromes	Physical Exam Findings
Non-coronary cardiac: • aortic stenosis • aortic regurgitation • hypertrophic cardiomyopathy	• **AS:** Characteristic systolic murmur, tardus or parvus carotid pulse • **AR:** Diastolic murmur at right of sternum, rapid carotid upstroke • **HCM:** Increased or displaced left ventricular impulse, prominent *a* wave in jugular venous pressure, systolic murmur that increases with Valsalva
Pericarditis/ Myocarditis	• **Pericarditis:** Fever, pleuritic chest pain, increased in supine position, friction rub • **Myocarditis:** Fever, chest pain, heart failure, S3
Esophagitis, peptic ulcer disease, gall bladder disease	• Epigastric tenderness • Right upper quadrant tenderness, Murphy's sign
Pneumonia	Fever, localized chest pain, may be pleuritic, friction rub may be present, regional dullness to percussion, egophony
Pneumothorax	Dyspnea and pain on inspiration, unilateral absence of breath sounds
Costochondritis, Tietze syndrome	Tenderness of costochondral joints
Herpes zoster	Pain in dermatomal distribution, triggered by touch; characteristic rash (unilateral and dermatomal distribution)

- **Abbreviations:** AR indicates aortic regurgitation; AS, aortic stenosis; HCM, hypertrophic cardiomyopathy; MR, mitral regurgitation; and S3, third heart sound.

What to do when patients present with chest pain …

to any medical facility setting?



In all patients who present with acute chest pain regardless of the setting, an ECG should be acquired and reviewed for STEMI within 10 minutes of arrival



In all patients presenting to the ED with acute chest pain and suspected ACS, cTn should be measured as soon as possible after presentation

- **Abbreviations:** ACS indicates acute coronary syndrome; cTn, cardiac troponin; ECG, electrocardiogram; ED, emergency department; HCP, healthcare provider; and STEMI, ST-segment elevation myocardial infarction.

Electrocardiographic-Directed Management of Chest Pain

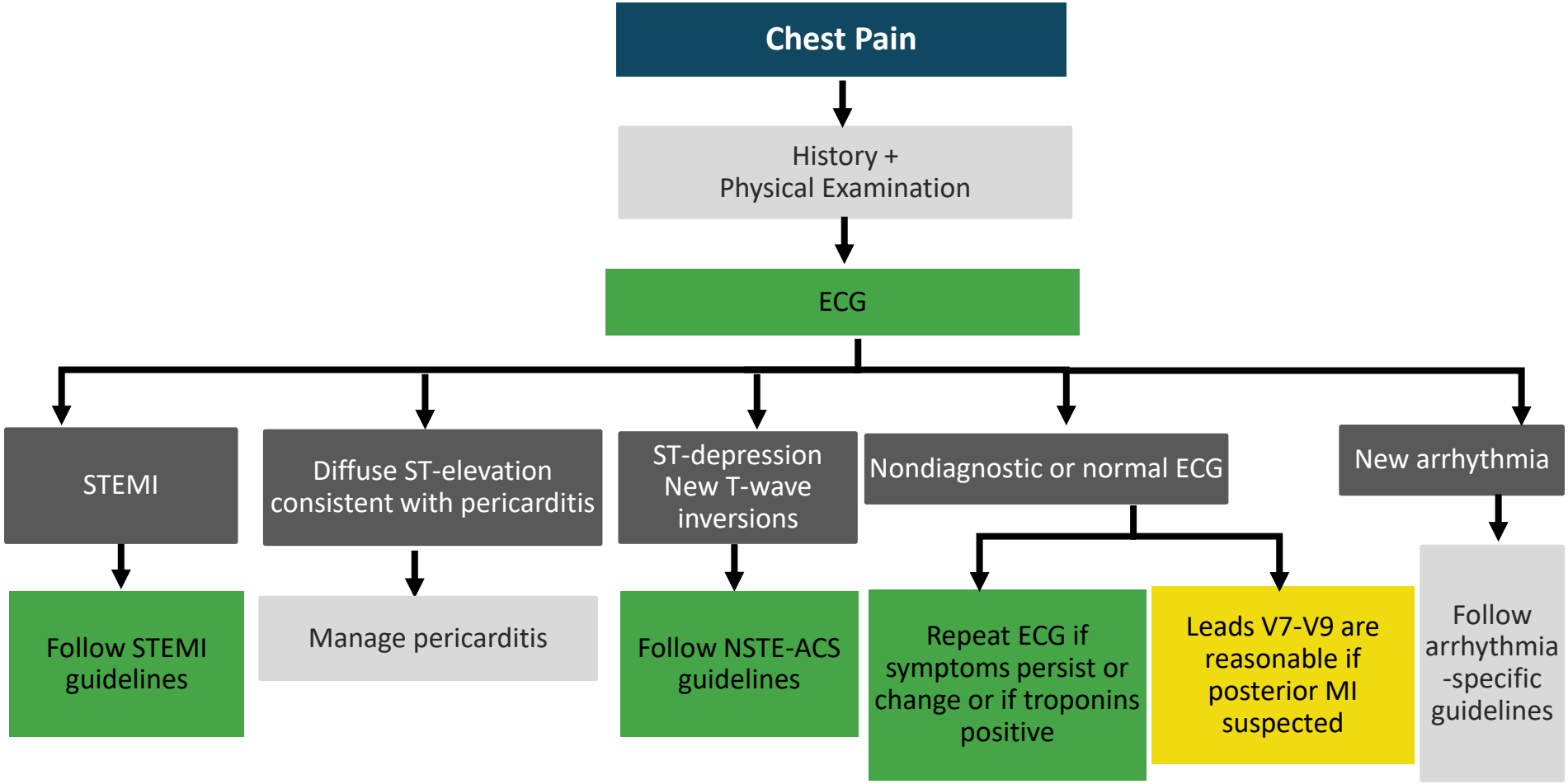

- **Abbreviations:** ECG indicates electrocardiogram; NSTE-ACS, non–ST-segment–elevation acute coronary syndrome; MI, myocardial infarction; and STEMI, ST-segment elevation myocardial infarction.

General Approach to Risk Stratification of Patients With Suspected ACS

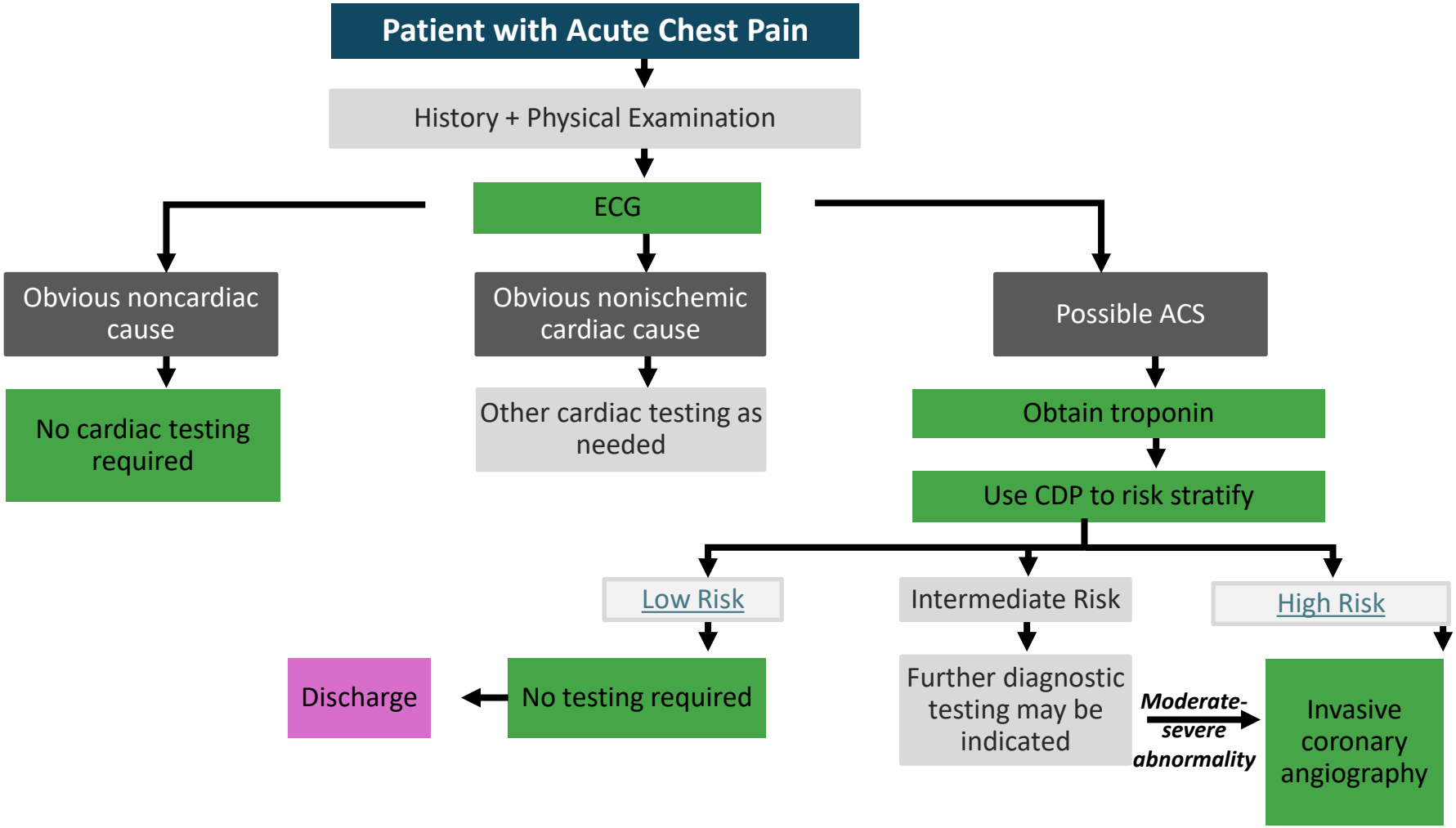

Abbreviations: ACS indicates acute coronary syndrome; CDP, clinical decision pathway; and ECG, electrocardiogram.

Overview of normal ECG

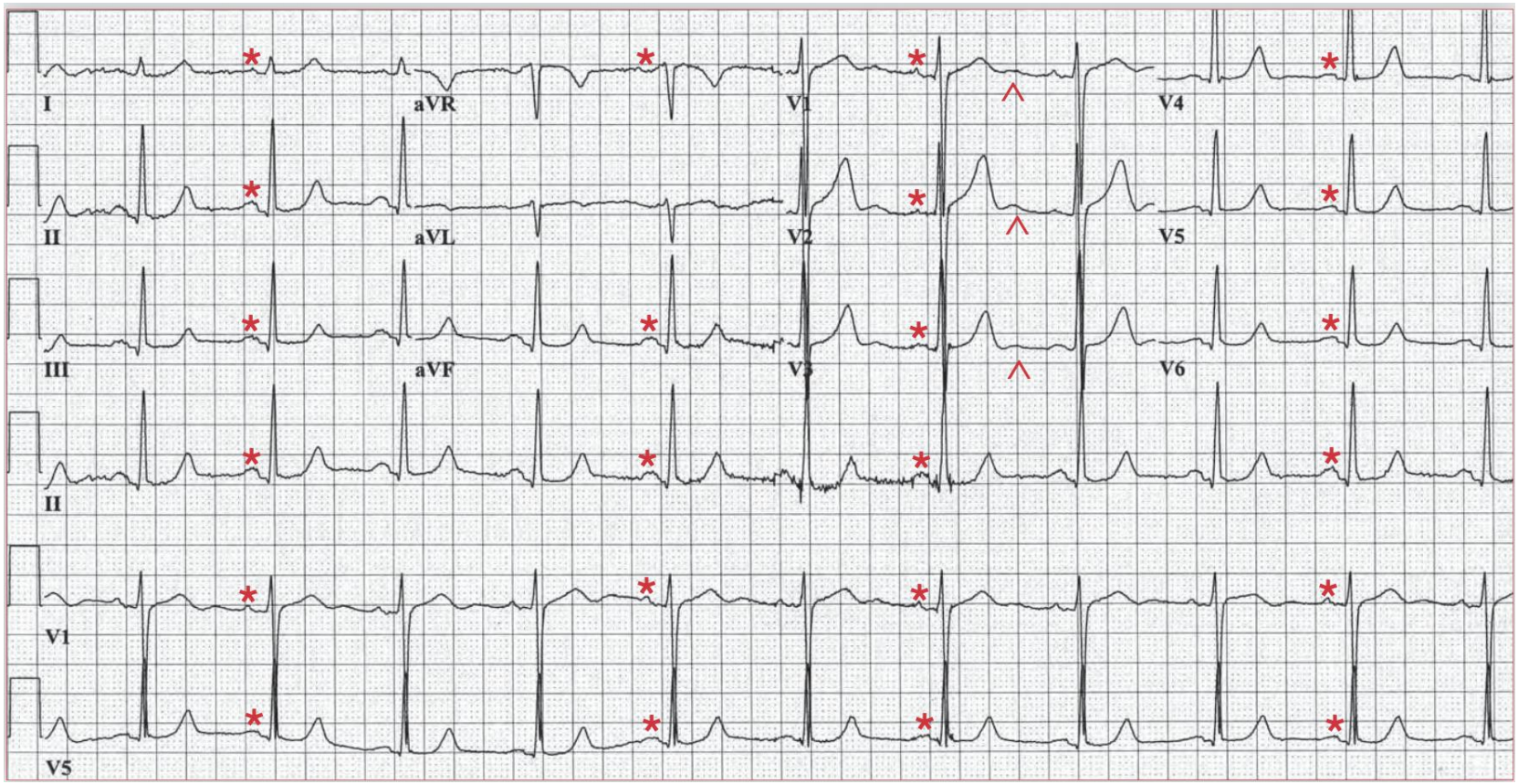

Ischemic Changes

T-waves, ST-segment, and Q-waves

T-waves

- Hyperacute (tall and peaked)
- Flattened
- Inverted (symmetrical)

ST-segments

- Elevated (Infarct)
- Depressed (Ischemia or Infarct)

Q-Waves

- Late change of Infarction

Evolutionary changes in OMI

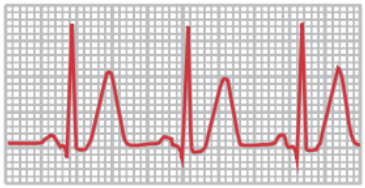

1. Earliest change is hyperacute (symmetric) T waves.

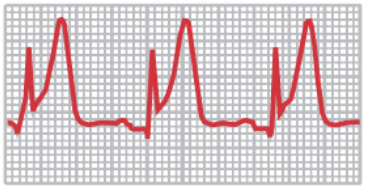

2. ST segments begin to elevate, maintaining ST segment concave morphology; hyperacute T waves still present.

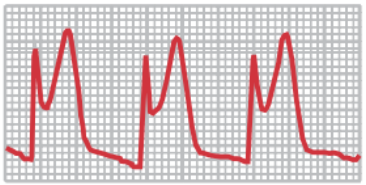

3. ST segments elevate farther and are still concave; hyperacute T waves still present.

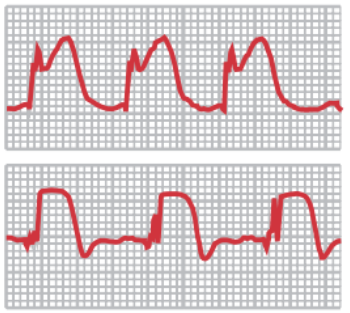

4. ST-segment elevation continues and ST segment becomes convex, merging with T wave; R-wave amplitude decreases.

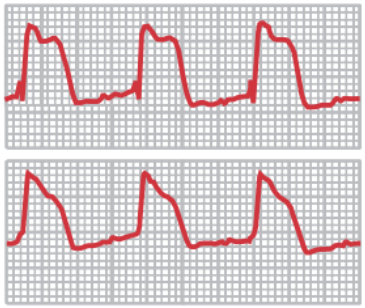

5. ST segments and T waves merged; R wave lost; complex has morphology of a "current of injury" and resembles the fast action potential.

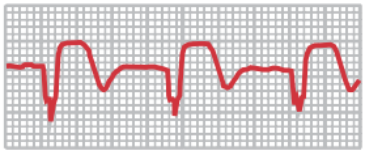

6. ST segments begin to return to baseline, Q waves develop and T waves begin to invert.

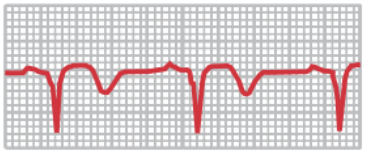

7. Chronic infarct pattern develops (ie, Q-wave and T-wave inversion).

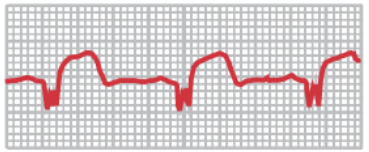

8. Persistent ST-segment elevation weeks after acute event indicates presence of aneurysm.

Ischemia – *T-Wave*

- Peaked T-waves
  - Ischemia, HyperK, LVH, LBBB

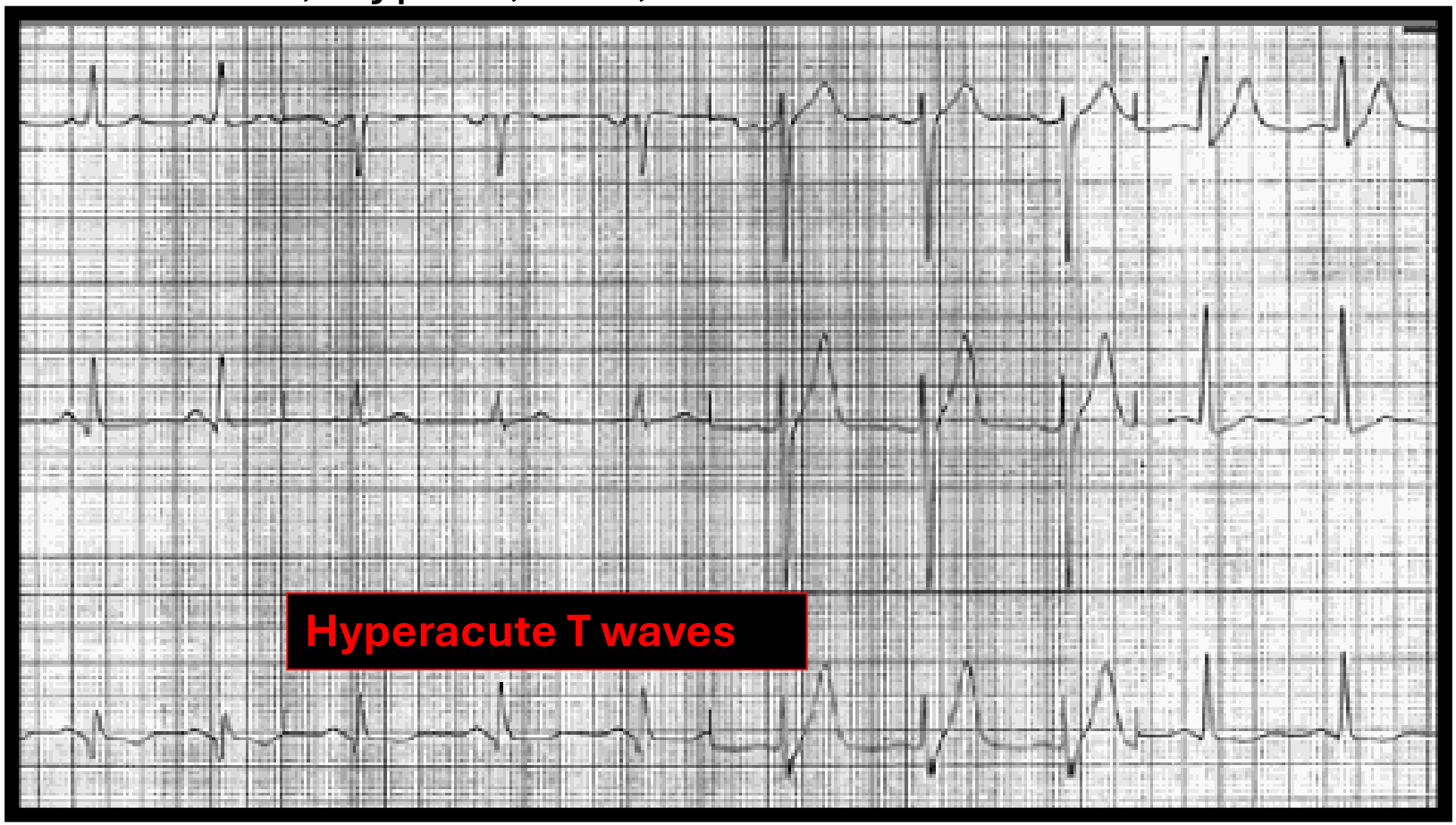

Ischemia – *T-Wave*

- Inverted T-waves
  - Ischemia (deep, symmetrical)
  - LVH, LBBB, myocarditis, pericarditis, contusion, high ICP, digoxin (asymmetrical)

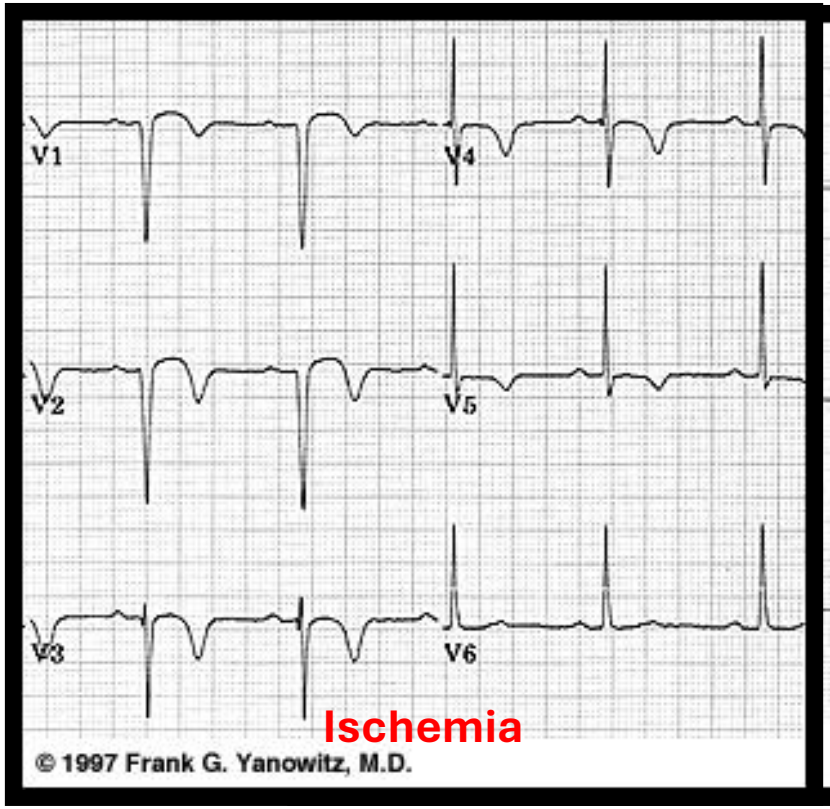

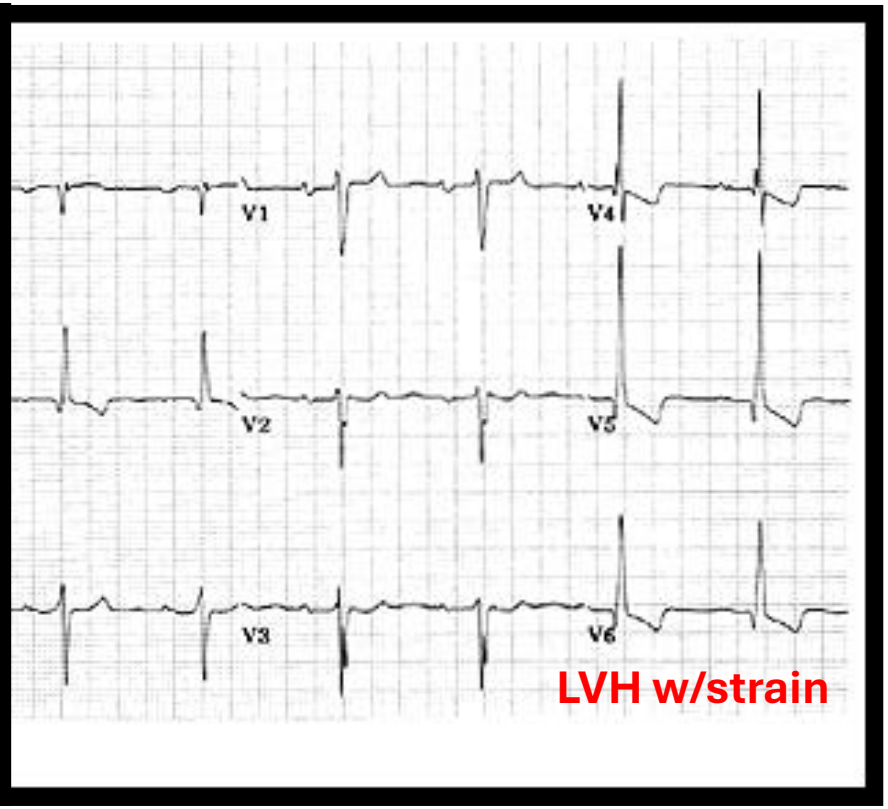

Ischemia – *ST-Segment*

- ST-segment Elevation
  - A change of Infarction (concave down)
  - DDx: Prinzmetal angina, Aneurysm, LBBB, Pericarditis, Hypothermia, Hyperkalemia, Benign early repolarization

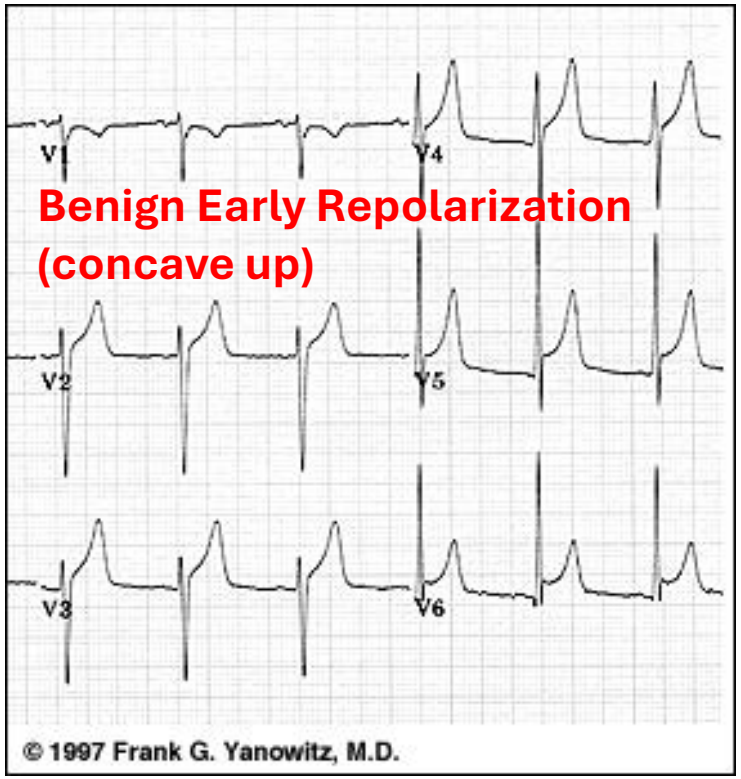

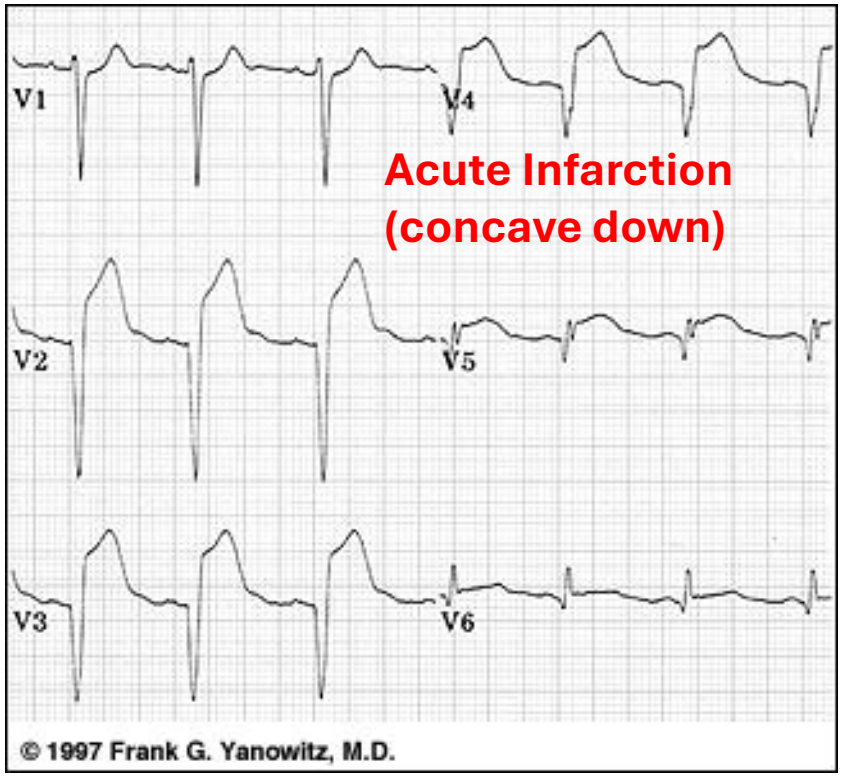

Ischemia – *ST-Segment*

- ST-segment depression
  - Ischemia or Infarction (horizontal or down-slope)
  - DDx: Reciprocal Infarct changes, Digoxin, LVH, hypokalemia, LBBB/RBBB

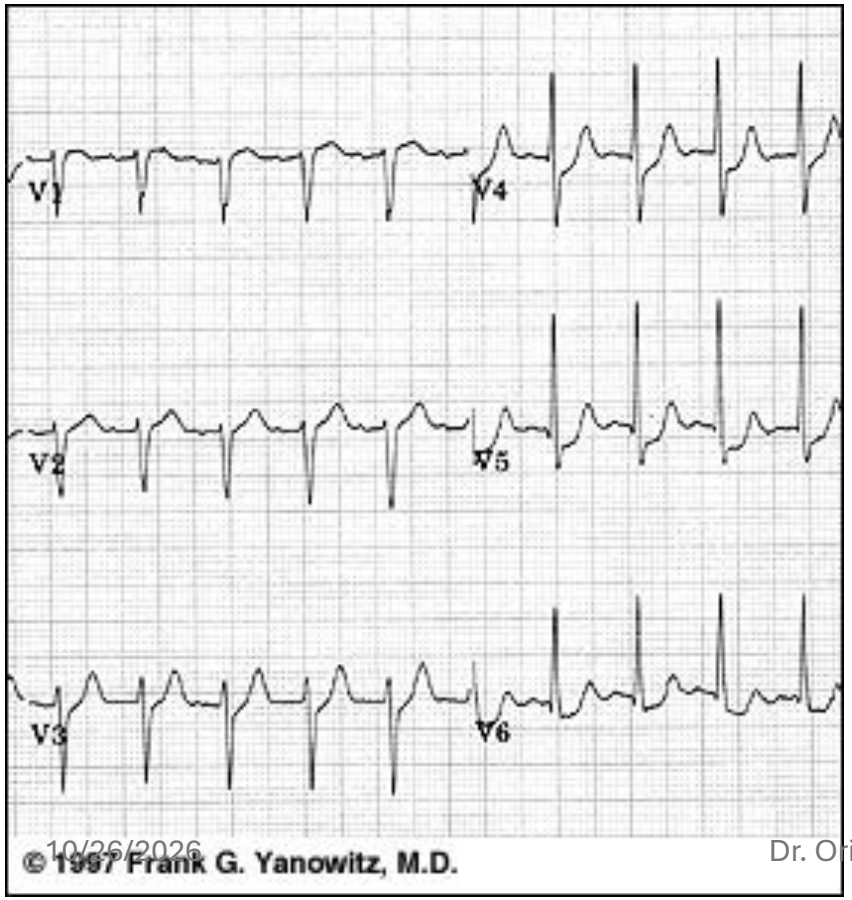

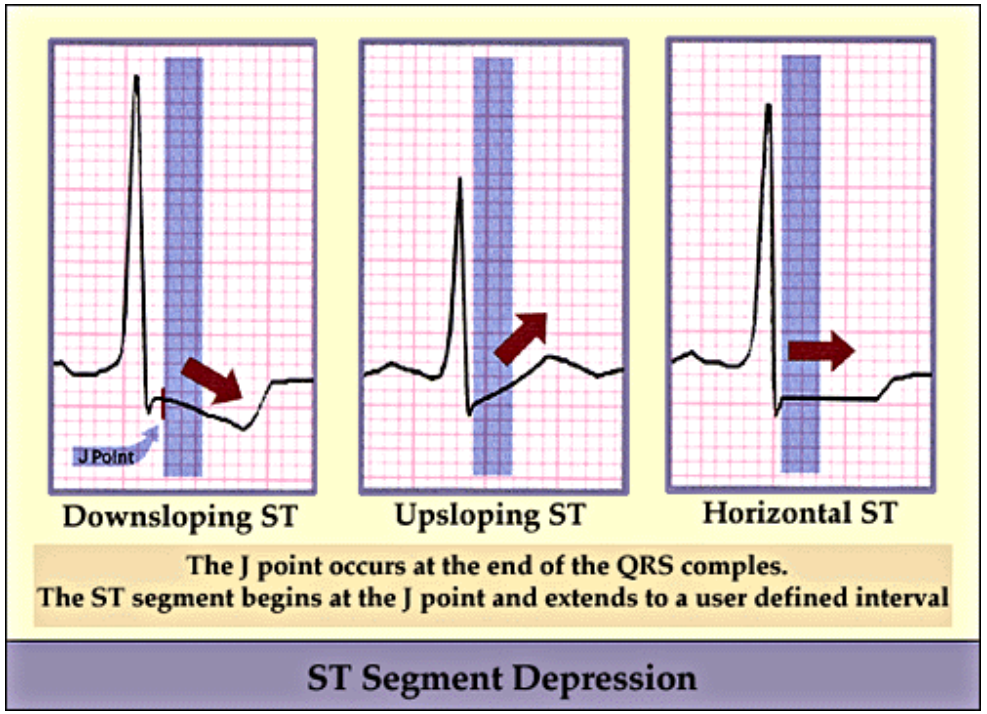

Ischemia – *Q-Waves*

- Q-waves
  - Indicates infarction
  - Occur several hours to days after infarct
  - Persist lifelong

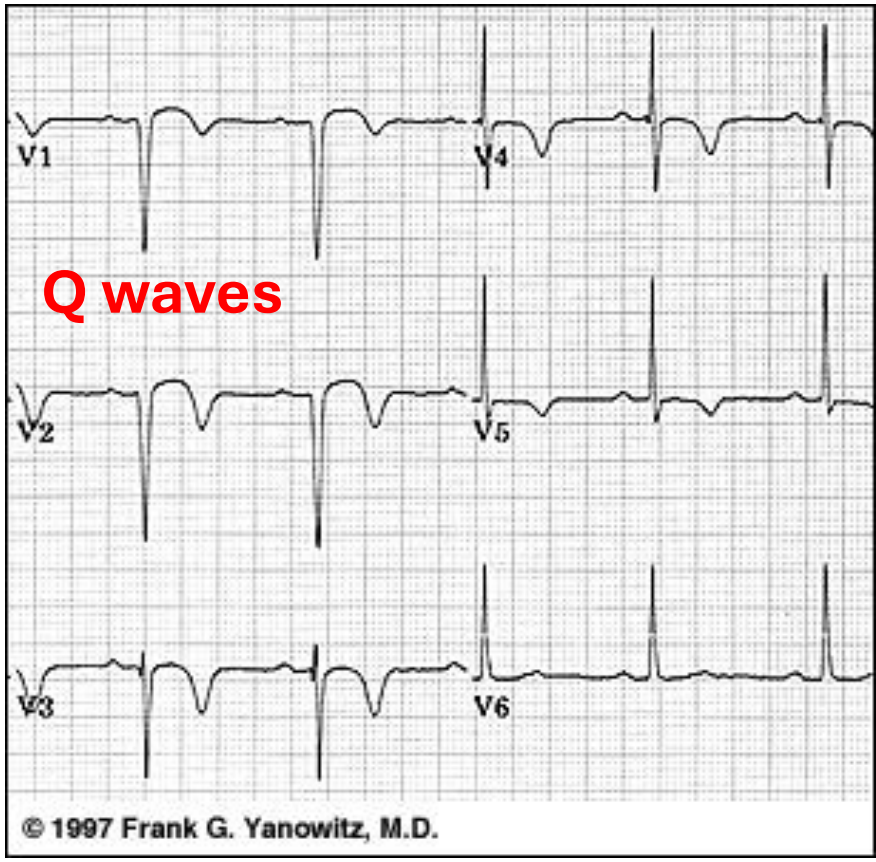

- Pathological Q
  - Ensure there is no R wave!
  - Should be > 0.04 s (1 small block)
  - Should be > 25% of the R wave amplitude

NOT Q waves (they are S waves)



Ischemic Changes

- Remember the anatomical correlations
  - Especially important when diagnosing ischemia or infarction



Ischemia – Examples

Acute Anterior ST-elevation MI

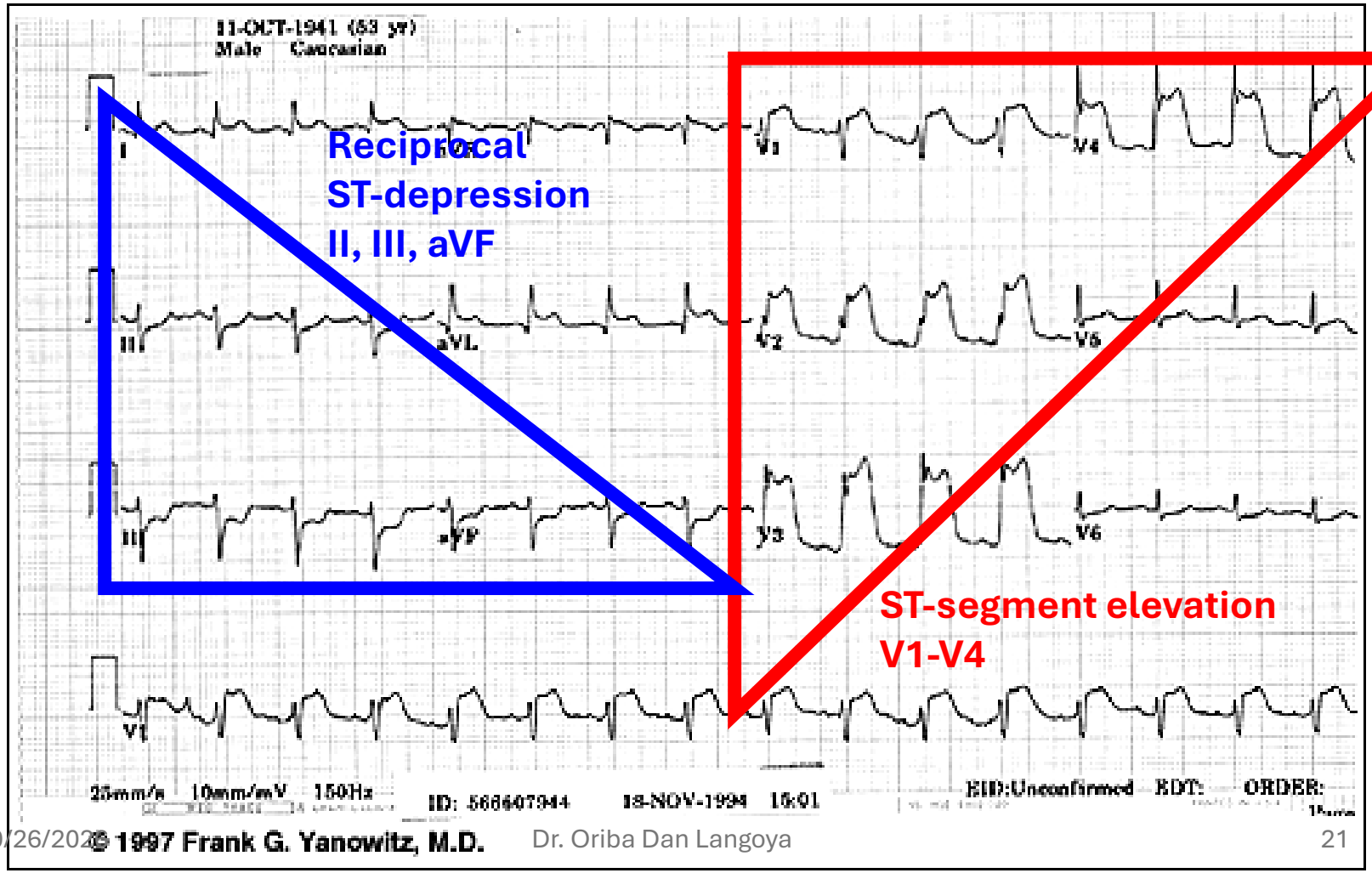

Ischemia – Examples

Acute Inferior ST-elevation MI

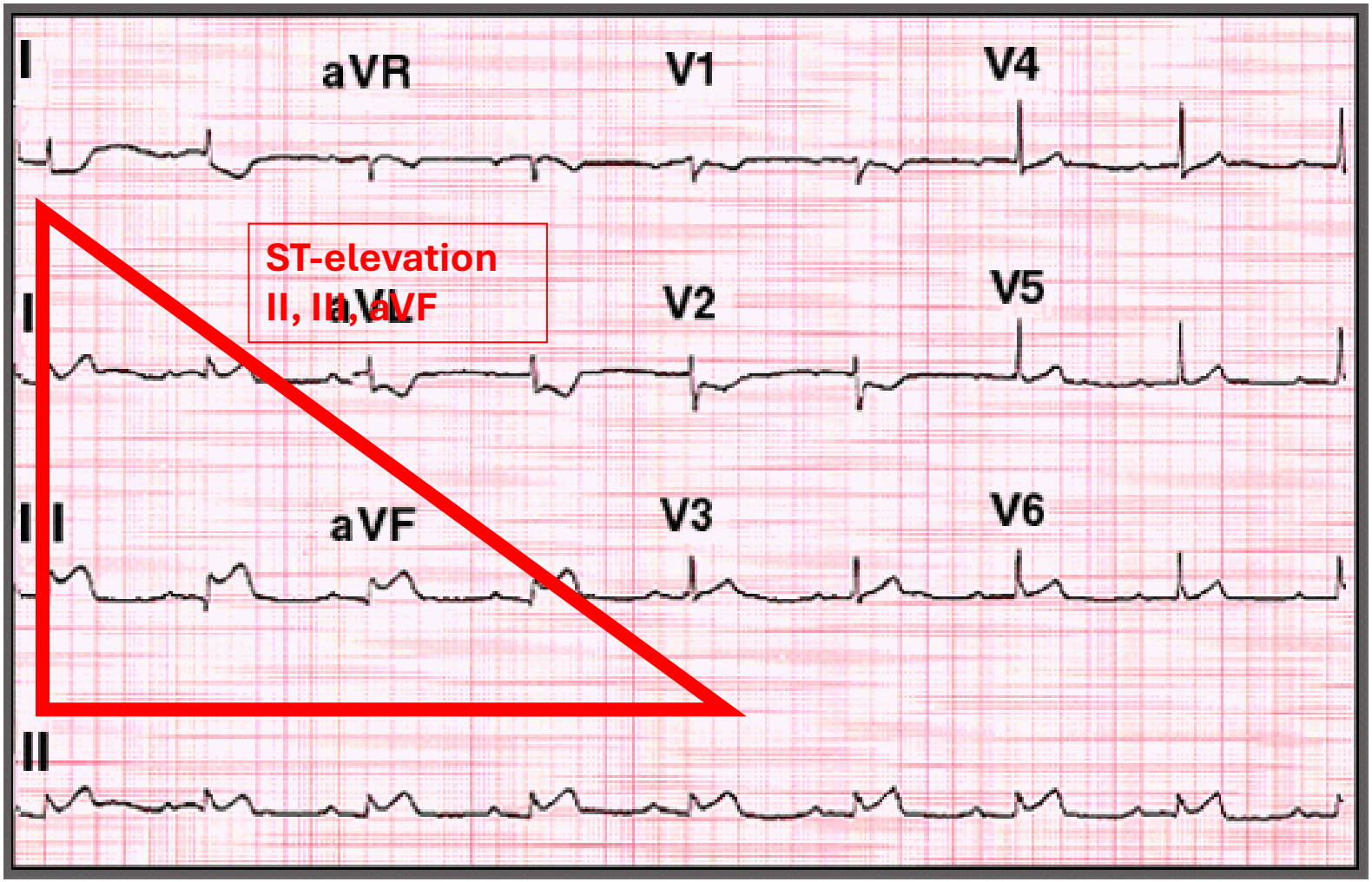

Ischemia – Examples

Old Inferolateral MI

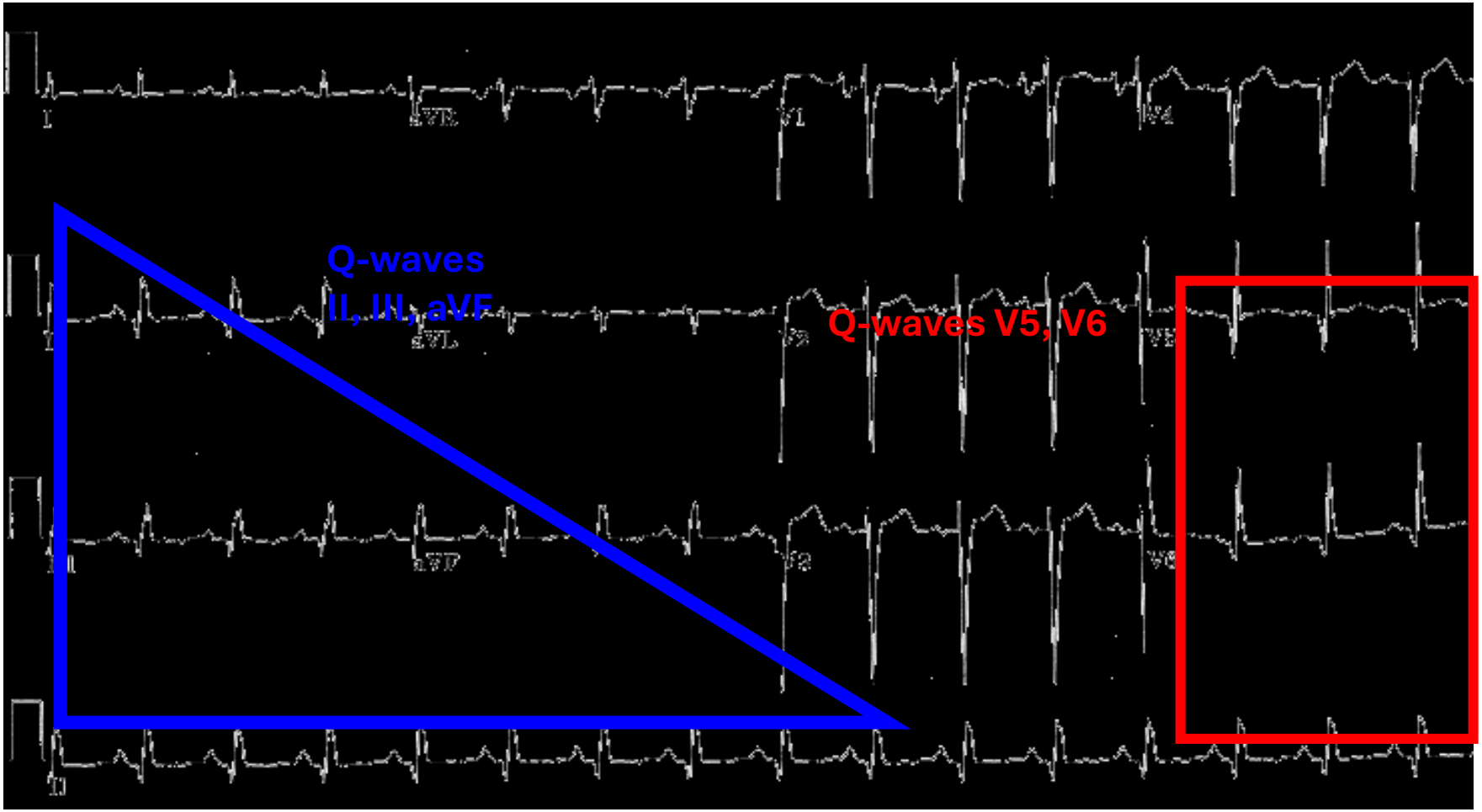

Dx: multivessel coronary disease

- 64y/F with DM, C/o atypical chest discomfort (left-sidedache). She has been taking a β-blocker for hypertension. ECG done

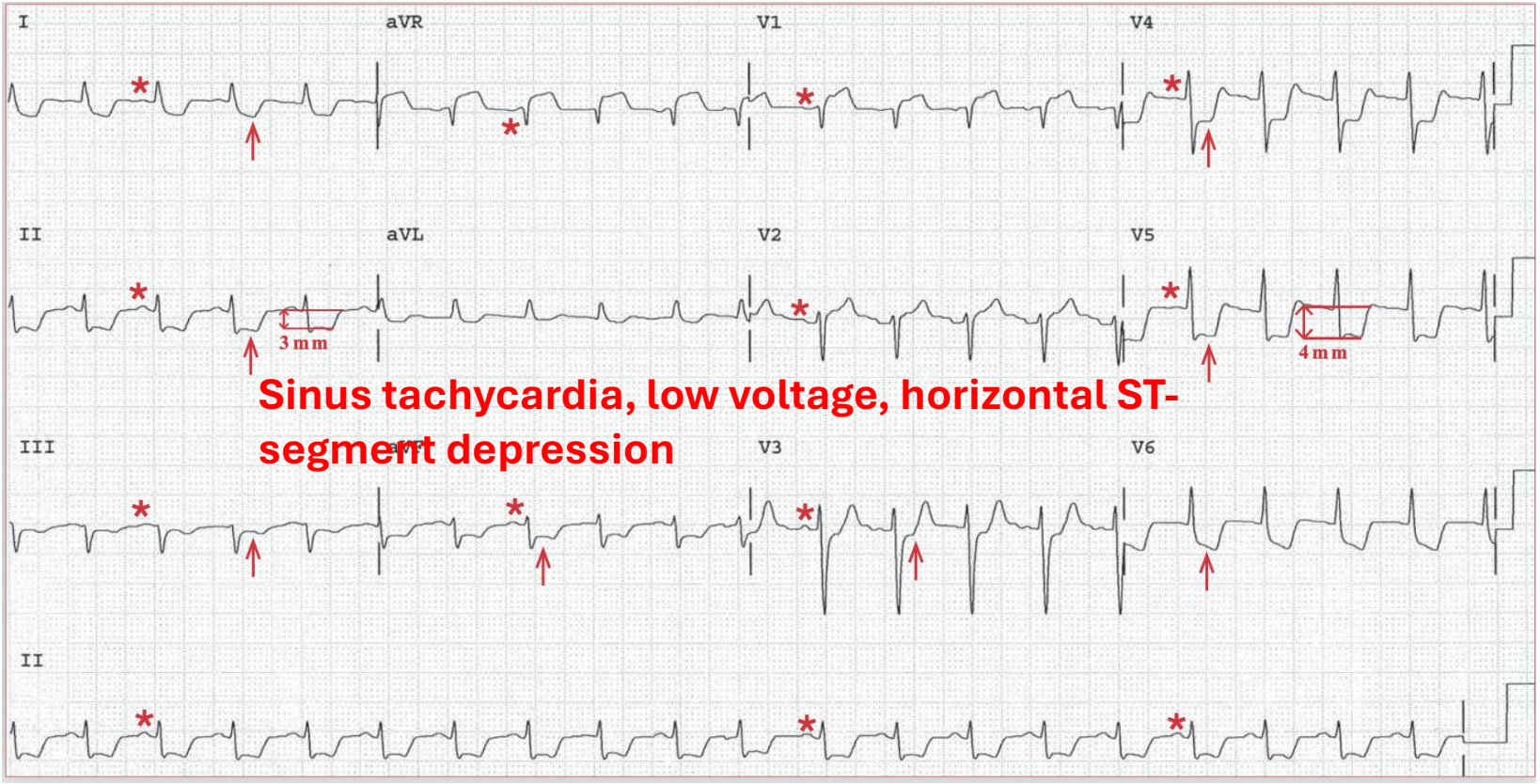

64yrs/M DM, acute onset of Chest pain, Dyspnea

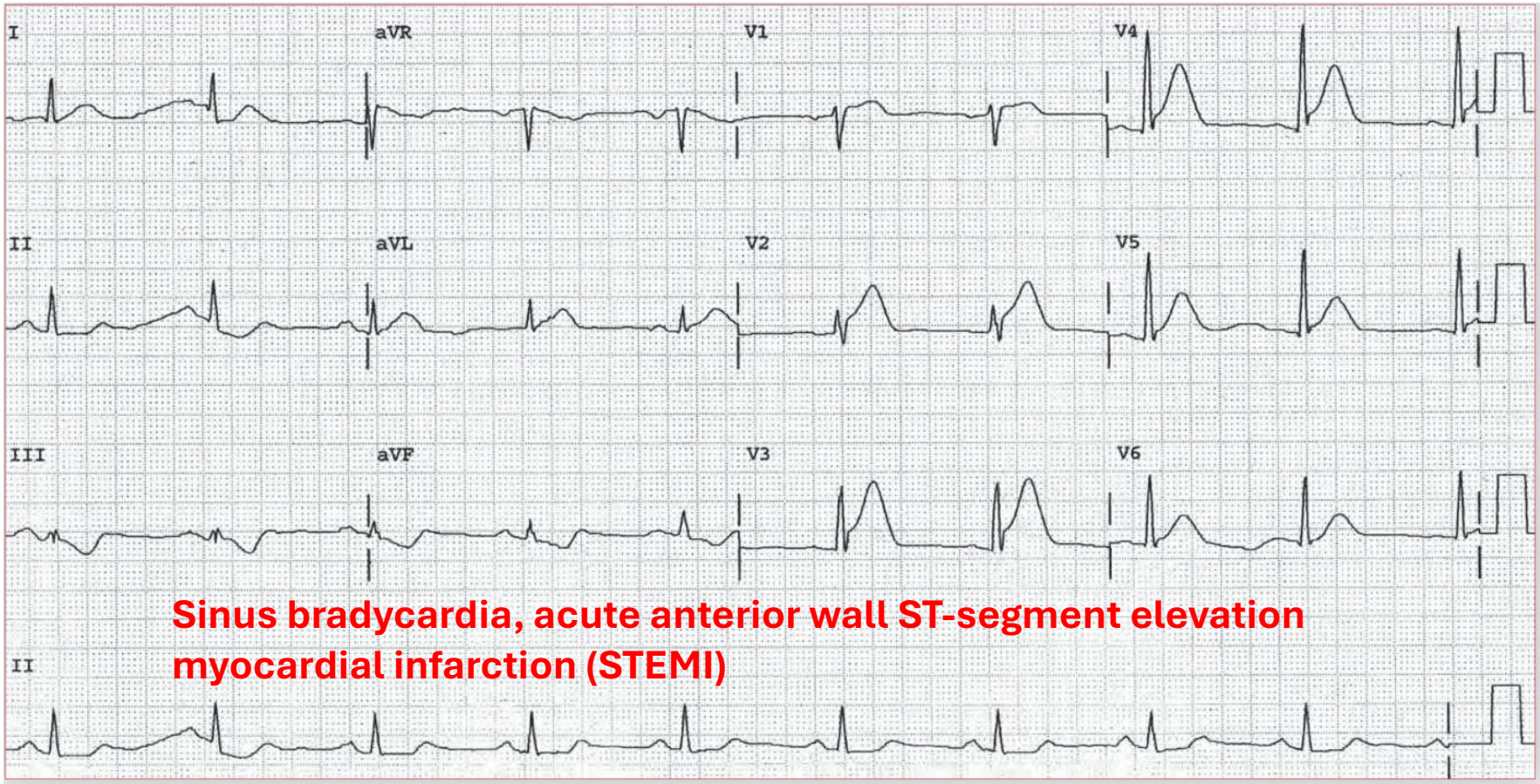

55yr/M with COPD, C/o: severe retrosternal chest tightness, diaphoresis & light headedness while eating lunch.

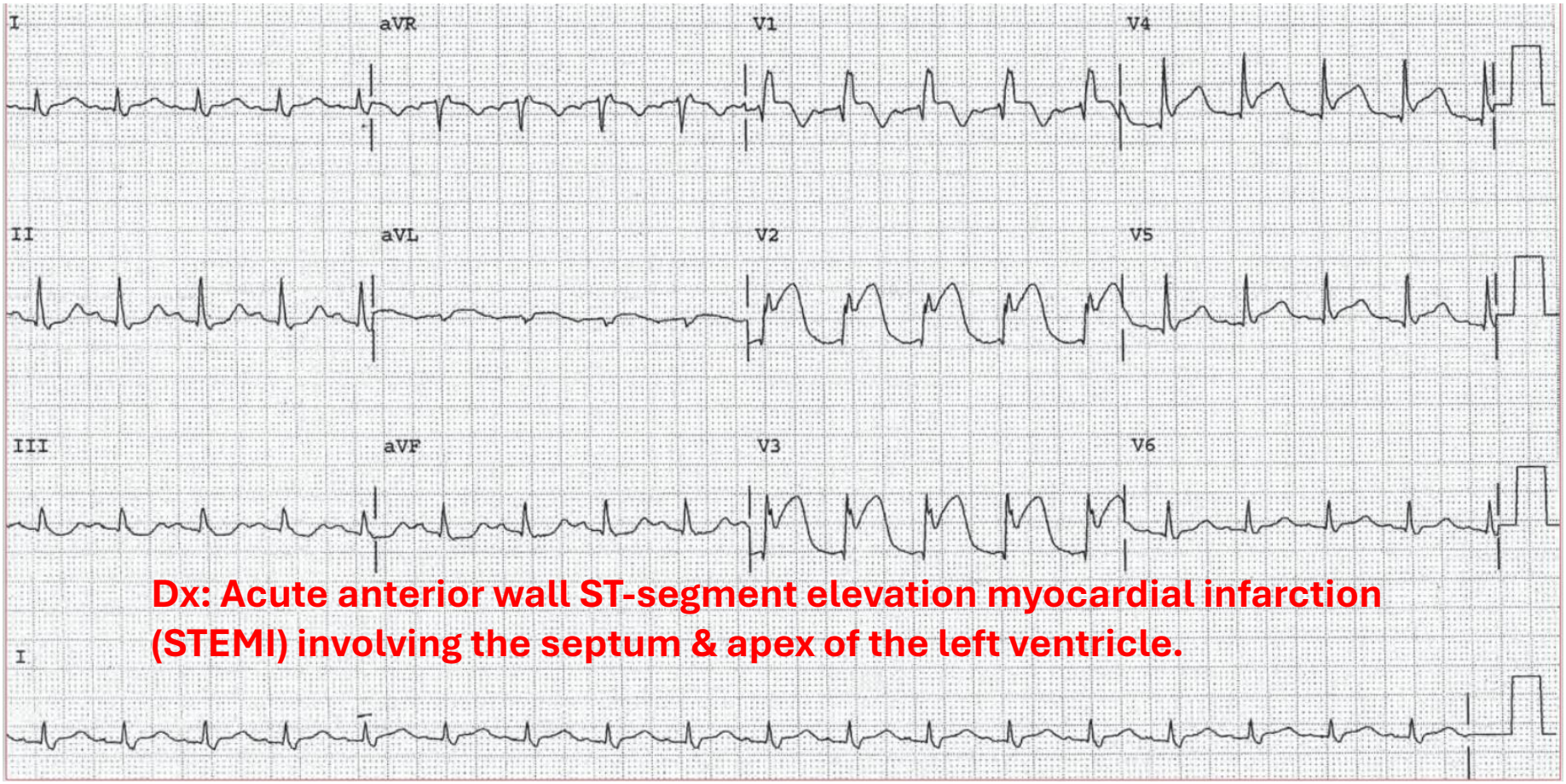

Dx: Acute anterior wall ST-segment elevation myocardial infarction (STEMI) involving the septum & apex of the left ventricle.

51yr/M DM, HHD uncontrolled, came with crushing chest pain at Emergency

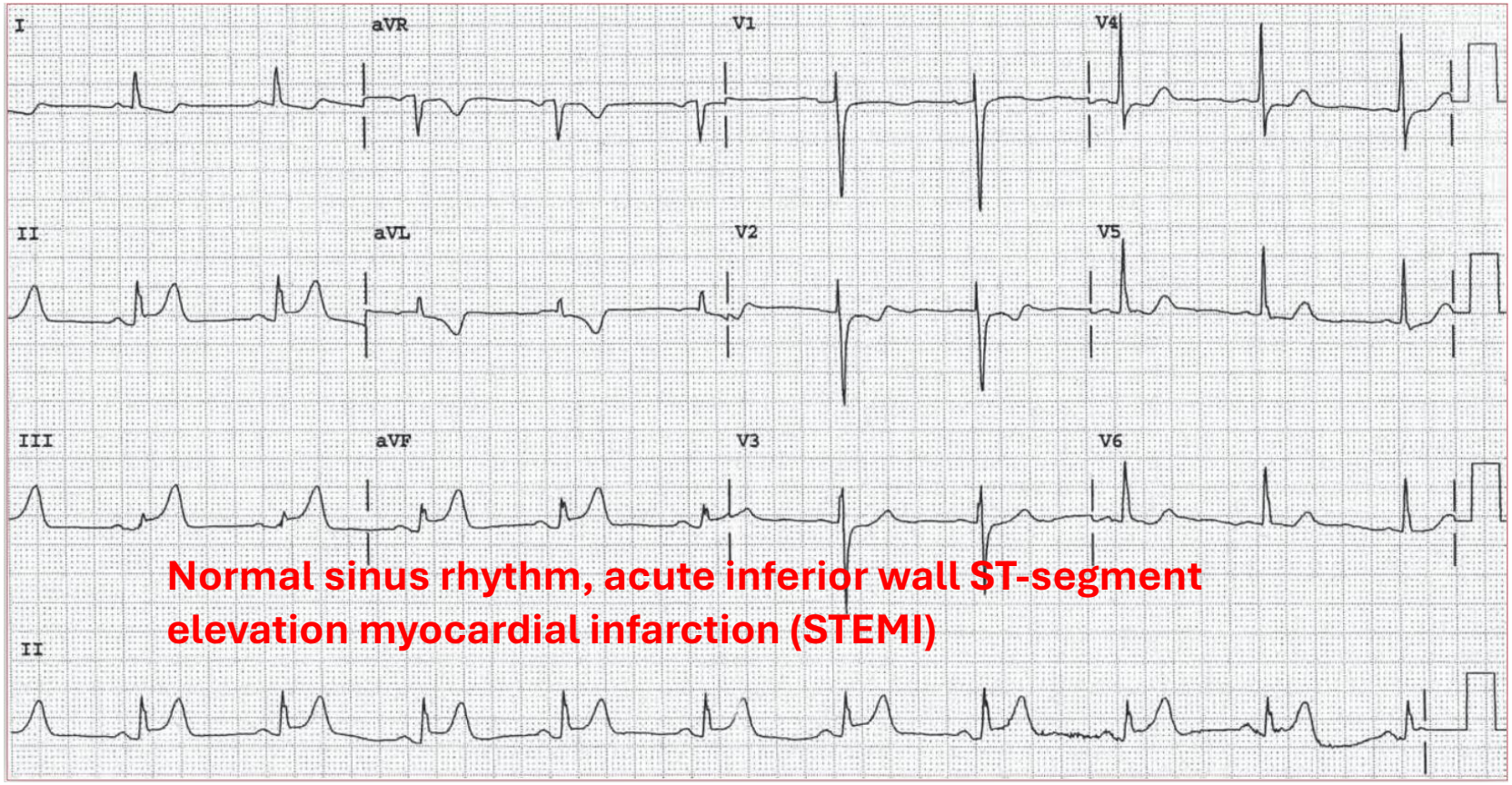

64y/M with HTN, came with chest pain & Dyspnea on Exertion

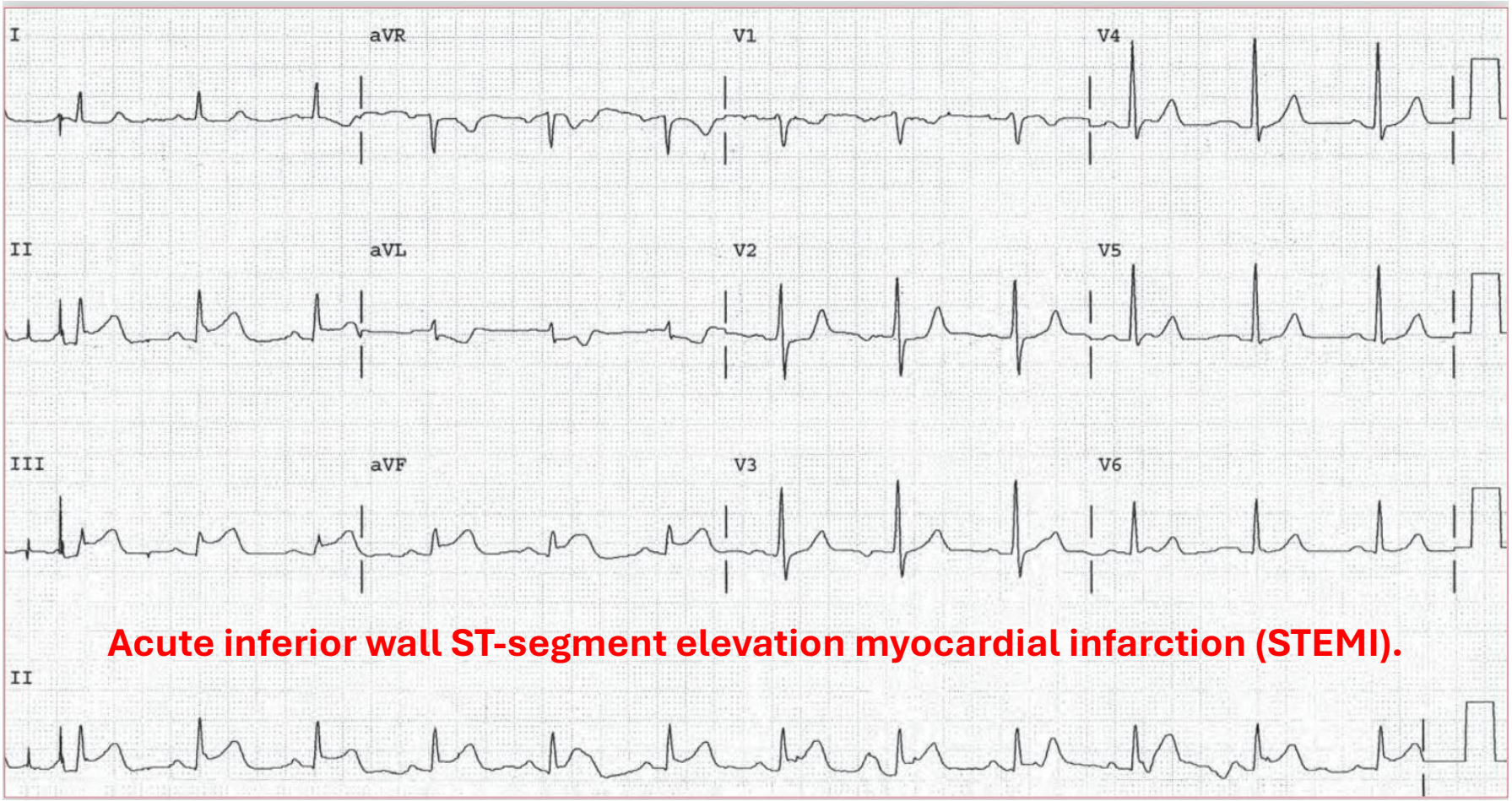

Acute inferior wall ST-segment elevation myocardial infarction (STEMI).

System goals and initial reperfusion treatment of patients with STEMI.

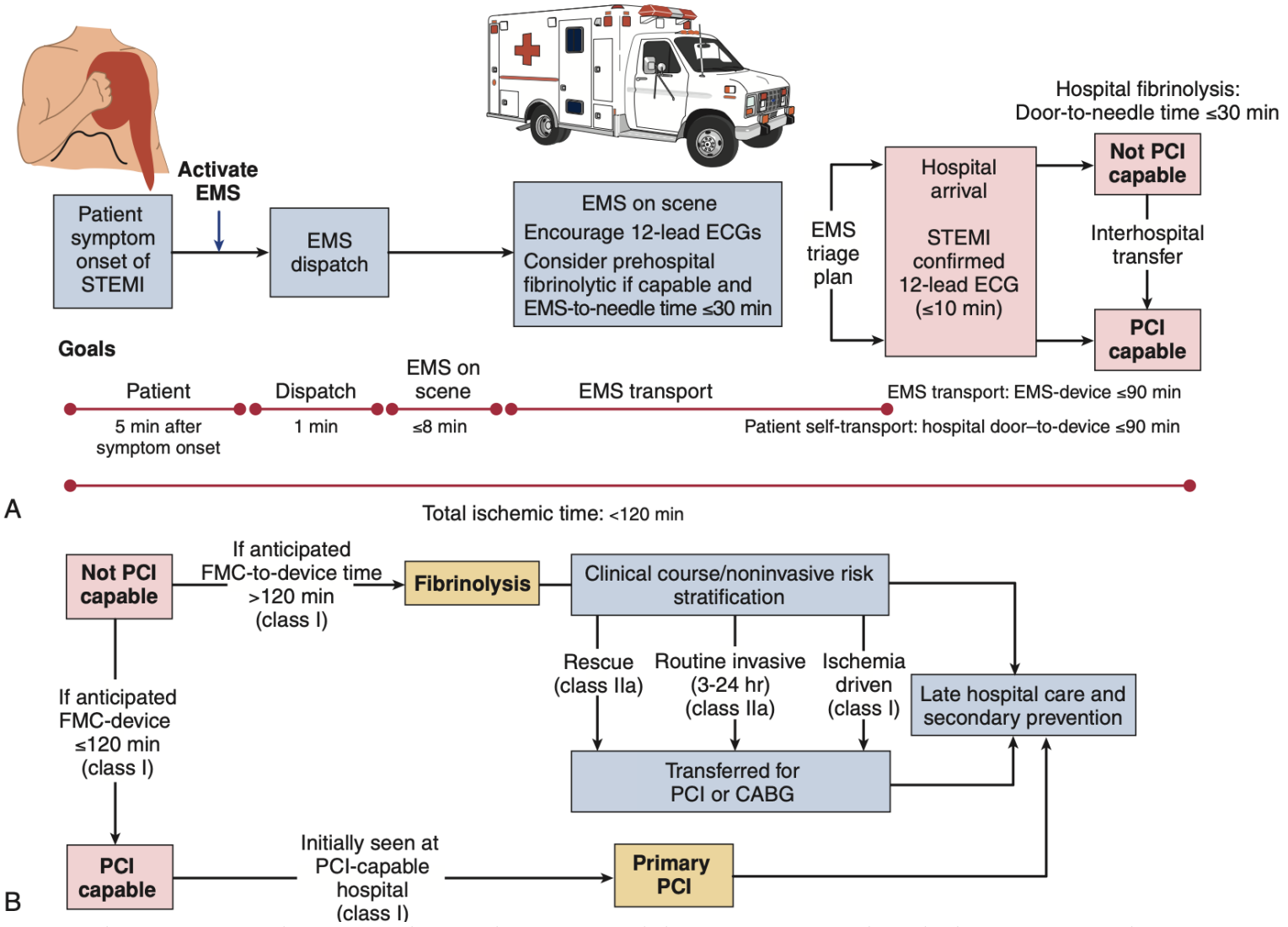

American College of Cardiology Foundation/ American Heart Association Task Force on Practice Guidelines. J Am Coll Cardiol 2013;61:e78.)

Pharmacologic Anti-Ischemic Therapies in Non–ST Elevation Acute Coronary Syndromes (NSTE-ACS)

CLASS OF MEDICATION	MECHANISM OF ACTION	CLINICAL EFFECTS IN NSTE-ACS
Traditional Therapies		
Beta blockers	Decrease heart rate, blood pressure, and contractility through antagonism of $beta_1$ receptors	Decrease mortality[51]
Nitrates	Decrease preload through venodilation; vasodilate coronary arteries	No benefit on mortality
Calcium channel blockers	May vasodilate, reduce heart rate, or decrease contractility depending on specific drug	No clear benefit on mortality or reinfarction Increased reinfarction rate when short-acting nifedipine is used alone
Newer and Experimental Therapies		
Ranolazine	Inhibits late inward sodium current	Decreases recurrent ischemia and arrhythmias
Trimetazidine	Shifts myocardial metabolism from fatty acid to glucose use	Decreases short-term mortality
Nicorandil	Activates ATP-sensitive K^+ channels and dilates arterioles; may have ischemic precondition-like effect	Decreases arrhythmias and transient ischemia
Cyclosporine	Inhibitor of the mitochondrial permeability transition pore involved in reperfusion injury	Reduces infarct size in small studies;* larger clinical trial in progress

*Mewton N, Croisille P, Gahide G, et al. Effect of cyclosporine on left ventricular remodeling after reperfused myocardial infarction. J Am Coll Cardiol 2010;55(12): 1200-5.

From American Heart Association; Soukouli V, Boden WE, Smith SC Jr, O'Gara PT. Nonantithrombotic medical options in acute coronary syndromes: old agents and new lines on the horizon. Circ Res 2014;114:1944-58.

Recommendations for Antithrombotic Agents in Patients with Non–ST Elevation ACS

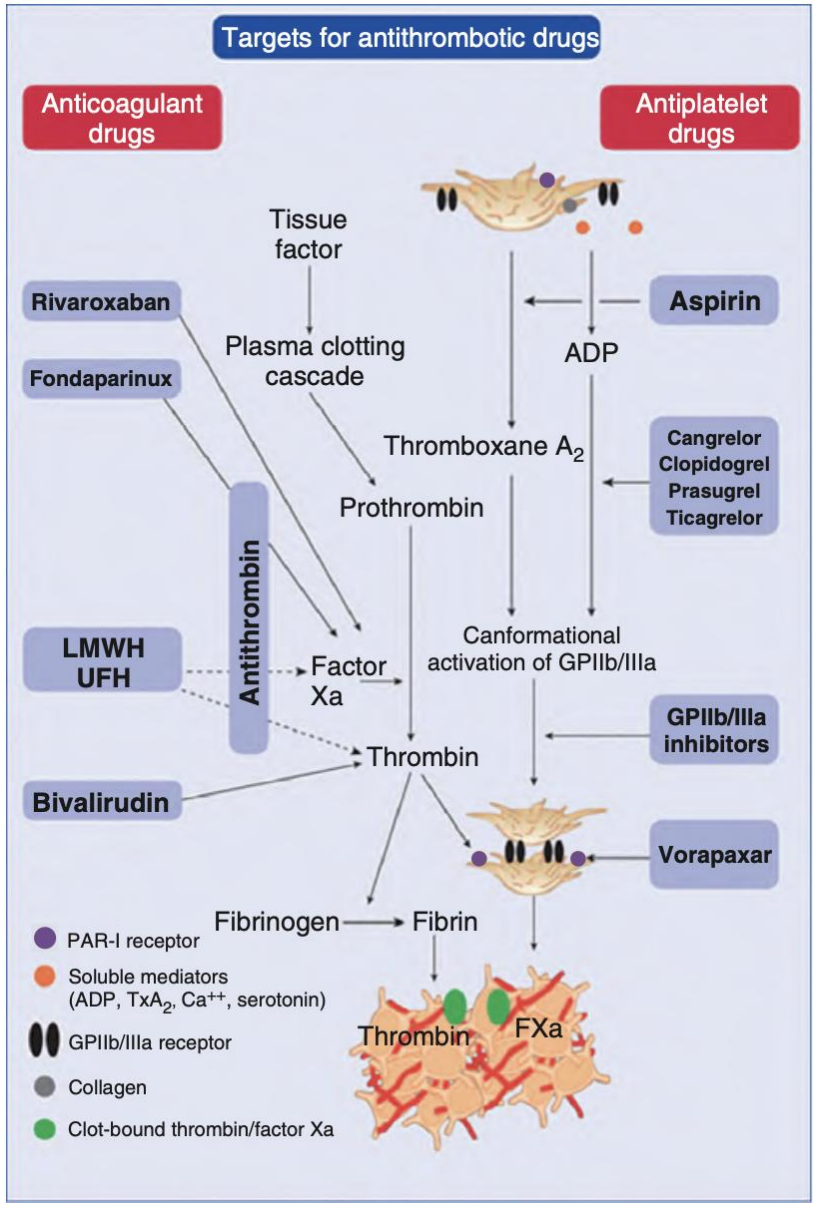

- Non–enteric-coated, chewable aspirin (162 to 325 mg) should be given to all patients without contraindications on presentation.
- Maintenance dose of aspirin (81 to 325 mg/day) continued indefinitely.
- In patients who are unable to take aspirin because of hypersensitivity or major gastrointestinal intolerance, a loading dose of clopidogrel (300 or 600 mg)
- Then followed by a daily maintenance dose of 75 mg should be substituted.

Enoxaparin is recommended at presentation, other option include unfractionated heparin (UFH) and fondaparinux. If an early invasive strategy is planned, bivalirudin is also an option.